

## ■ Original article

## The effects of topical vitamin C solution on the necrotic tissue volume of burn wounds

Hamid Rabat Sarpooshi<sup>1</sup>, Mojtaba Vaheb<sup>2</sup>, Yasser Tabarayee<sup>3</sup>, Ali Vahidi Sabzevar<sup>4</sup>, Forough Mortazavi<sup>5\*</sup>

(Received: 24 Apr 2016; Accepted: 22 Jun 2016)

### Abstract

**Background and Purpose:** Vitamin C is administered orally or intravenously for the treatment of burn wounds. However, effects of the topical application of vitamin C remain unclear. This study aimed to evaluate the effects of topical vitamin C solution on the necrotic tissue volume of second-degree burn wounds.

**Methods:** This clinical trial was conducted on 30 patients with second-degree burns admitted to the burn unit of Vasee Hospital of Sabzevar, Iran. Burn wound areas were divided into two parts, receiving routine treatment with sulfadiazine ointment and vitamin C in addition to sulfadiazine. After cleaning the wounds, dressings were replaced daily. Depth of burn wounds in each area was observed to be similar. Burn wounds were examined on days one, three, seven and 14 after the burn incidents using Bates-Jensen Wound Assessment Tool. Data analysis was performed in SPSS version 20 using repeated measures ANOVA.

**Results:** In patients of the experimental area, mean volume of necrotic tissue was  $1.033 \pm 0.182$  at baseline, while it reached  $1.233 \pm 0.430$  on day 14 after the incident. In the control group, mean volume of necrotic tissue was  $1.000 \pm 0.000$  at baseline, while it increased to  $1.700 \pm 0.794$  on day 14 after the incident. On day 14, a significant difference was observed between the experimental and control groups in this regard ( $P=0.018$ ;  $f=5.982$ ).

**Conclusion:** According to the results of this study, topical administration of vitamin C could be largely effective in the treatment of second-degree burn wounds.

**Keywords:** Burn, Necrotic tissue volume, Topical vitamin C solution, Wound

### Introduction

Burn is the damage that occurs in the skin or mucous membranes, including the lining of the mouth or stomach conjunctiva and airways, which is caused by excessive heat or cold, chemical agents, and electrocution. In most cases, in addition to skin damage, burning might lead to systemic disorders in the body and affect structures such as muscles, bones, nerves and blood vessels (1).

Necrotic tissues exist in different forms, including

stiff scars with dry and leathery texture and compact layers. If the wound remains moist, non-living tissues appear as soft and brown, yellow or gray, which are referred to as grime areas. Moreover, pus might be firmly attached to the wound bed or edges containing fibrin, bacteria, healthy leukocytes, cellular debris, serous exudates and large volumes of DNA. After scar removal, the pus often becomes visible. Moisture preservation is essential since

<sup>1</sup> School of Nursing & Midwifery, Sabzevar University of Medical Sciences, Sabzevar, Iran

<sup>2</sup> Department of Plastic and Reconstructive Surgery, Faculty of Medicine, Sabzevar University of Medical Sciences, Sabzevar, Iran

<sup>3</sup> Department of Health, School of Public Health, Sabzevar University of Medical Sciences, Sabzevar, Iran

<sup>4</sup> Petroleum Industry Health Organization, Sarakhs, Iran

<sup>5,\*</sup> Corresponding author: Department of Midwifery, School of Nursing & Midwifery, Sabzevar University of Medical Sciences, Sabzevar, Iran. Email: fmortazavi@yahoo.com

exposure to air causes pus dehydration and backing of stiffness and fatty mode (2).

Healing of burn wounds is a major issue in medical sciences, and researchers have been concerned with finding new drugs with minimal side effects to treat burn wounds (3). According to statistics, 2.5 million Americans suffer from burn injuries each year, and approximately 100,000 patients are hospitalized due to these injuries. In addition, more than 10,000 people lose their lives due to burn complications, which accounts for the highest rate of mortality after traffic accidents (4, 5).

In Iran, 725,000 burn incidents occur annually, and 48,000 patients are hospitalized due to these incidents. Moreover, eight people were reported to die each day due to burn injuries in 2002 in Iran. Percentage of burn injury deaths in our country is almost three times higher compared to the Eastern Mediterranean region, while twice higher than the global mortality rate (6).

In the city of Sabzevar, located in the northeastern Iran, 152 patients were admitted in the burn unit of Vasee Hospital in 2014. However, this rate reached 190 cases since the beginning of 2015 until the end of November 2016, which is suggestive of the increased number of burn injuries in this city.

Burn wound care involves the topical administration of antimicrobial agents with basic dressing in order to absorb wound exudates and other outer skin layers (7). Today, various types of dressing are used for burn wound healing (8), and topical antibiotics are commonly applied to limit colony growth and control pathogenic organisms (9). Furthermore, debridement is used in the treatment of acute and chronic wounds (2). Necrotic tissues, pus, scarring and infections are indications for the application of wound debridement. However, debridement is not used on the bedsores of heels (covered by dry scars) and stable, dry ischemic ulcers (2).

Silver sulfadiazine is a topical antibiotic cream commonly applied in the treatment of burn injuries. This drug has bactericidal and bacteriostatic properties, and over the past 50 years, it has been shown to have remarkable therapeutic effects on burn injuries (2). Some of the side effects of silver sulfadiazine include pain, burning, itching, rashes,

and reversible leucopenia (10). Numerous synthetic drugs are used for the treatment of burn wounds, which are often expensive and lead to complications such as allergies and drug resistance. Therefore, researchers have been attempting to discover alternative medicines for this purpose (3).

Water-soluble vitamin C is essential for the synthesis of collagen and intracellular environment of cells, tissues, blood vessels, cartilage, bones, teeth, skin and tendons. Moreover, it increases the protective mechanism of the immune system and facilitates wound healing (10).

Vitamin C, also known as ascorbic acid, is the most efficient water-soluble antioxidant. Vitamin C protects the skin against ultraviolet rays, free radicals and other damages. In addition to its anti-inflammatory effects, vitamin C is an agent of skin depigmentation (11). Infusion of vitamin C is considered beneficial in the treatment of burn injury patients since it reduces the need for fluid resuscitation. This agent is normally used via oral administration in burn patients (12).

Unlike most animals, humans are not able to synthesize ascorbic acid in their body; as such, they should consume vitamin C on a daily basis (10). Previous studies performed on pigs have confirmed that the application of 10% vitamin C solution on the skin could increase the concentration of this vitamin in the skin (11, 13). Moreover, evidence attests to the efficacy of the intravenous and oral administration of vitamin C in the treatment of burn injuries (14, 15).

Dressing of burn wounds using silver sulfadiazine ointment might have toxic effects on the restoration of keratinocytes since it adheres to the wound surface and produces pseudo-scars, which hinders the process of wound healing. Therefore, new medications with limited side effects and reduced treatment costs are required for patients with burn injuries.

In previous studies, topical vitamin C solution has been only used as a supplementary treatment for bedsores and burns in animal models, and its effect on human burn injuries have not been assessed. On the other hand, vitamin C solution has been applied in the treatment of erythema after carbon dioxide laser, as well as chronic corneal wound healing.

This study aimed to evaluate the effects of topical vitamin C solution on the necrotic tissue volume of patients with burn injuries.

## Materials and Methods

This clinical trial was conducted on 30 patients with second-degree burns (two or more organs/extended limb burn) admitted in the burn unit of Vasee Hospital of Sabzevar, Iran in 2016. Written informed consent was obtained from all the patients prior to the study.

Considering that multiple factors are involved in wound restoration and infection, this study was conducted on two parallel groups. This study was conducted on two symmetric body parts or an extended burn area in a patient using sulfadiazine ointment and combined sulfadiazine ointment and vitamin C, respectively. Upper-limb extended burn areas were treated with silver sulfadiazine, while lower-limb burn areas were treated with combined vitamin C and silver sulfadiazine. Maximum limb level of the two burn areas under study was determined at less than 20%. In addition, depth of each burn wound area was found to be similar in the selected patients. A subspecialist of plastic surgery observed and examined the burn wounds during each stage of the study.

After debridement and washing the wounds with water and normal saline solution, limbs or sections of burn wounds were dried using sterile gauze. Afterwards, 1% silver sulfadiazine ointment was applied to the wounds using sterile gloves (thickness: 1.5 mm). As for the other limbs and body parts under study, washing and drying were performed similarly, and 10% solution of topical vitamin C was applied on the surface of the wounds using a sterile swab to a maximum area of 225 square centimeters. To dress the burn wounds, 1% silver sulfadiazine ointment was applied to the wounds (thickness: 1.5 mm) using sterile gloves. Additionally, we used 5-ml vials containing 500 mg of vitamin C (Daroopaksh Company, Iran).

In this study, healing of the necrotic tissue volume was assessed on days one, three, seven, and 14 after the burning incidents. While replacing the dressing, the wounds were closely examined by a

specialist based on the parameters of Bates-Jensen Wound Assessment Tool. To control observer bias, digital photos were taken during the treatment and immediately evaluated by a specialist. After the completion of checklists, improvement of the two organs was compared accordingly.

## Research instruments

Data collection tools included demographic questionnaires and Bates-Jensen Wound Assessment Tool (BWAT).

BWAT is a valid instrument, and its paper format has been used in several healthcare settings for standardizing wound assessment and documentation of wound status (16). This scale consists of 15 phrases to measure the outcomes of current treatments (16). Two of these phrases focus on the location and shape of the wound, which are not scored in this scale. Moreover, BWAT is composed of five sections (13 items), which are scored based on a five-point Likert scale. In this questionnaire, the lowest score represents the most favorable wound condition, and the highest score is indicative of the least favorable wound status.

In this study, healing process of necrotic tissue volume was evaluated through analyzing the obtained scores of BWAT. Ulcers were scored within a range of 1-5, and the final score was recorded. Validity of BWAT has been confirmed in previous studies for the Iranian population (17, 18).

## Statistical analysis

Collected data were encoded, and after monitoring and ensuring of accuracy, data analysis was performed in SPSS version 16 using repeated measures ANOVA to investigate the effect of vitamin C on wound healing. In addition, Mauchly's test was used to evaluate the homogeneity of variances.

## Ethical considerations

Study protocol was approved by the Ethics Committee of Sabzevar University of Medical Sciences (code: IR.MEDSAB.REC.1394.60), and official permit was obtained from hospital authorities. Moreover, objectives of the study were explained to participants, and written informed

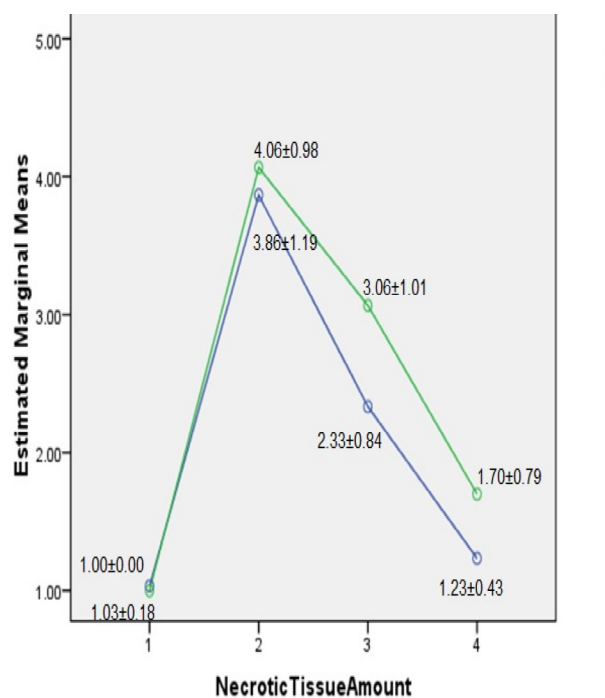
consent was obtained from all the patients prior to the study. Patients were allowed to withdraw from the study at any time, and researchers ensured that study objectives were in line with the values and beliefs of the participants. Researchers of this study were obliged to inform the officials and participants regarding the final results of the study (IRCT2015101224487N1).

## Results

Sample size of this study consisted of 30 patients, including 18 men (60%) and 12 women (40%), admitted in the burn unit of Vasee Hospital of Sabzevar city, Iran. Mean age of the patients was  $43.03 \pm 11.9$  years, and mean body mass index was  $27.82 \pm 4.080$  kg/m<sup>2</sup>.

Healing of necrotic tissue volume in each type of treatment was measured based on the parameters of BWAT on days one, three, seven and 14 after the burn incident (16). In addition, repeated measures ANOVA was applied to investigate the effects of vitamin C on wound healing. To evaluate the homogeneity of variances, we used Mauchly's test, the assumption testing of which was rejected at 99% confidence level ( $P < 0.001$ ). Freedom degree of repeated measures ANOVA was adjusted via Epsilon testing. Since this test is conservative for small sample sizes, Greenhouse Epsilon was applied to assess its effects. Data obtained through this approach were indicative of differences in the healing process of necrotic tissue volume in various measures with each dressing type ( $P < 0.001$ ).

Considering the partial eta square of 0.805, the treatment used in this study captured approximately 80% of wound changes. After differentiation therapy of burn wounds with vitamin C and sulfadiazine, a



**Figure 1.** Chart of differences between two treatment type

significant difference was observed between the two study groups in terms of the healing of necrotic tissue volume ( $P < 0.001$ ). In other words, with partial eta square of 0.061, ulcer change was reported to be approximately 6% (Table 1).

According to our findings, rate of necrotic tissue volume healing was different between the two groups ( $P = 0.018$ ) (Table 2). The difference between the two treatments with partial eta square of 0.093 explained 9% of the variance of wound changes. In addition, areas administered with topical vitamin C showed better recovery compared to other areas, especially on days seven and 14 after the burning incident (Figure 1).

In this study, we assessed the differences of the mean and standard deviation of wound healing on various days. On the first and third day, no significant

**Table 1.** Tests of within-subject effects

Source	Test	Df	Mean square	F	P-value	Partial eta square
Score	Greenhouse-Geisser	1.977	160.216	239.835	0.000	0.805
Score *type	Greenhouse-Geisser	1.977	2.502	3.745	0.027	0.061

**Table 2.** Tests of between-subject effects

Source	test	Df	Mean square	F	P-value	Partial eta square
Type	Greenhouse-Geisser	1	7.004	5.982	0.018	0.093

differences were observed between the mean values, while a significant difference was reported on days seven and 14 after the burn incident (2.333 and 1.233 in topical vitamin C treatment group, respectively). In the silver sulfadiazine group, these values were determined at 3.066 and 1.700 on days seven and 14, respectively, and the highest rate was observed on day seven after the burn incident.

## Discussion

The present study aimed to investigate the effect of topical vitamin C solution on the necrotic tissue volume of burn wounds in 30 patients admitted in the burn unit of Vasee Hospital of Sabzevar, Iran. According to the results, there was a significant reduction in the volume of necrotic tissues after treatment with topical vitamin C solution, which is in congruence with the findings of previous studies in this regard.

Findings of the current research are consistent with the study by Woessner et al., who claimed that topical vitamin C could promote the development of fresh, plentiful granulation tissue in bedsores. Formation of this granulation tissue started on the seventh day of treatment with topical vitamin C, leading to the progress of the healing process (19). In the mentioned study, treatment with Vitamin C solution initiated shortly after a two-week therapy with no improvement, and the results suggested that vitamin C solution plays a pivotal role in collagen formation, and oral intake could enhance its effects.

In another research by Lima et al. conducted on mice, wound inflammation was reported to be lower in the intervention group, while granulation tissue and collagen fiber formation were higher. Furthermore, fewer macrophages and more new vessels were observed in the intervention group compared to the control group, and ulcer edges had greater improvement in the intervention group (2).

In the mentioned study, inflammation rate and number of collagen fibers and vessels were examined microscopically, which was not possible in the present study. Nevertheless, the results of the aforementioned studies confirm that utilization of vitamin C solution leads to the advanced recovery

of granulation and wound margins, which is in line with the findings of the current research.

In another study, Alester et al. investigated the effect of vitamin C on erythema after the application of carbon dioxide laser, and the results indicated that vitamin C significantly influenced the recovery of erythema (20). Our findings in this regard are consistent with the study by Alester et al., which suggested that in the treatment of burn wounds, efficacy of vitamin C solution surpasses the ointment form.

In another study, Parol Sink investigated the effect of topical vitamin C on resistant corneal ulcers and reported that the recovery process improved after the administration of 10% topical vitamin C, along with maintenance therapy (21), in the experimental group. Furthermore, results of the mentioned study indicated that vitamin C solution could reduce inflammation and enhance the recovery of corneal ulcers. This is in line with the findings of the current research since we observed the positive effects of vitamin C solution on the recovery of necrotic tissue volume.

Vitamin C is an eliminator of free radicals and could induce further improvement of burn wounds. One of the main functions of vitamin C is to build collagen for skin tissues. Collagen synthesis is the most vital process needed after burning incidents. Although the daily required dose of vitamin C is 60 mg, some experts argue that this amount of vitamin C is insufficient, especially if the body is under additional stress caused by incidents such as burning. As such, most medical experts recommend 250-1000 mg of vitamin C as the safe, daily dose (15).

### *Study limitations and strengths*

One of the limitations of the present study was lack of burn patients with bilateral burn or extended burn wounds, which resulted in the prolonged duration of sampling. It is recommended that future studies in this regard be performed in the burn units of major hospitals on larger sample sizes.

One of the strengths of our study was controlling the effects of confounding variables through designing a clinical trial, in which each patient was his/her own control to explore the effects of vitamin C on burn wounds.

## Conclusion

This study aimed to investigate the effect of topical vitamin C solution on the reduction of necrotic tissue volume of burn wounds. Our findings confirmed the hypothesis that this solution is able to decrease the necrotic tissue volume of burn wounds. These results could lay the ground for future studies regarding burn wound healing.

Use of topical vitamin C accelerates the healing of necrotic tissue volume, reduces the length of hospital stay, and decreases infections and mortality. Our findings could be applied effectively in other sciences, such as the pharmaceutical industry to manufacture topical medications for wound healing and food industry to use vitamin C as a food additive. In conclusion, it is recommended that the results of this study be taken into account in different methods of burn wound healing and construction of effective drugs, along with the application of topical vitamin C.

## Conflicts of interest

None declared.

## Authors' contributions

H. Robat Sarpooshi was the main investigator and contributed with drafting of the proposal, data collection, and drafting of the first manuscript. F. Mortazavi performed study design and critical revision of the manuscript. M. Vaheb supervised burn wound healing assessment; Y. Tabarayee carried out statistical analysis, and A. Vahidi Sabzevar contributed with data collection.

## Acknowledgments

Hereby, we extend our gratitude to Sabzevar University of Medical Sciences for the financial support of this study. We would also like to thank all the patients and personnel of Vasee Hospital of Sabzevar for assisting us in this research project.

## References

1. Guo S, Dipietro L. Factors affecting wound healing. *J Dent*

Res 2010; 89(3):219-29.

2. Lima CC, Pereira AP, Silva JR, Oliveira LS, Resck M, Grechi CO, et al. Ascorbic acid for the healing of skin wounds in rats. *Braz J Biol* 2009; 69(4):1195-201.
3. Malek HS, Ghaffarzadegan R, Alizadeh SA, Ghaffarzadegan R, Hajiagaei R, Ahmadi M. Effect of aloe vera gel, compared to 1% silver sulfadiazine cream on second-degree burn wound healing. *Complement Med J Facul Nurs Midwifery* 2013; 3(1):67-78 (Persian).
4. Martineau L, Shek PN. Evaluation of a bi-layer wound dressing for burn care I. Cooling and wound healing properties. *Burns* 2006; 32(1):70-6.
5. Demling RH, Way LW. *Burns and other thermal injuries*. New York: McGraw Hill; 2002.
6. Kooshiar H, Abbaspour H, Motamed Al Shariati SM, Rakhshandeh H, Khajavi Rad A, Esmaily H, et al. Topical effectiveness of kiwifruit versus fibrinolysin ointment on removal of necrotic tissue of full-thickness burns in male rats. *Dermatol Ther* 2012; 25(6):621-5 (Persian).
7. Urden LD, Stacy KM, Lough ME. *Thelan's critical care nursing*. Eugene, Spain: Diagnosis and Management; 2006.
8. Smeltzer SC, Bare BG, Hinkle JL, Cheever KH, Townsend MC, Gould B. *Brunner & Suddarth's Text book of medical-surgical nursing*. 11<sup>th</sup> ed. Philadelphia: Lippincott, Williams and Wilkins; 2008.
9. Hassanpour Avajji E. *Foundations for the burn*. Tehran: Shahid Beheshti University of Medical Sciences; 2013 (Persian).
10. Abgoon M. *Generic drugs of Iran*. Tehran: Noore Danesh; 2000 (Persian).
11. Telang P. Vitamin C in dermatology. *Indian Dermatol Online J* 2013; 4(2):143-6.
12. David N. Herndon. *Total burn care*. New York: Elsevier Health Sciences; 2007.
13. Draelos ZD. Nutrition and enhancing youthful-appearing skin. *Clin Dermatol* 2012; 28(4):400-8.
14. Dubick MA, Williams C, Elgio GI, Kramer GC. High-dose vitamin C infusion reduces fluid requirements in the resuscitation of burn-injured sheep. *Shock* 2005; 24(2):139-44.
15. Feinstein A. *Prevention's healing with vitamins: the most effective vitamin and mineral treatments for everyday health problems and serious disease*. 1<sup>st</sup> ed. New York: Rodale Books; 2013.
16. Harris C, Bates-Jensen B, Parslow N, Raizman R, Singh M, Ketchen R. Bates-Jensen wound assessment tool: pictorial guide validation project. *J Wound Ostomy Continence Nurs* 2010; 37(3):253-9.
17. Panahi Y, Izadi M, Sayyadi N, Rezaee R, Jonaidi-Jafari N, Beiraghdar F, et al. Comparative trial of Aloe vera/olive oil combination cream versus phenytoin cream in the treatment of chronic wounds. *J Wound Care* 2015; 24(10):459-60.
18. Arbastan MA, Rahzani K, Hekmatpou D, Alizadeh SA, Rafiei M, Malekiran AA. The effect of oral Melissa officinalis on serum oxidative stress and second degree burn wounds healing. *Health* 2014; 6(18):2517-24.

19. Mester AJ. Treatment of bedsores and chronic ulcers with topical ascorbic acid. *Lancet* 1961; 277(7172):343-4.
20. Alster TS, West TB. Effect of topical vitamin C on postoperative carbon dioxide laser resurfacing erythema. *Dermatol Surg* 1998; 24(3):331-4.
21. Singh P, Singh P, Talhar S, Sontakke BR, Bokariya P, Tarnekar AM, et al. Role of topical ascorbic acid in management of refractory corneal ulcer. *IOSR J Pharm* 2012; 2(6):1-4.